

Endocrinology

A COMPENDIUM OF LEADING ARTICLES IN THE FIELD OF VETERINARY ENDOCRINOLOGY SELECTED FOR THE VETERINARY PRACTITIONER

IN THIS ISSUE

- 1 Hypothalamic-Hypophyseal Disorders**
 - Plasma Pituitary Prohormones and Pituitary Adenoma Size in Cushing's Disease
 - Melanotroph Pituitary Adenoma with Diabetes Mellitus
- 4 Tests of Thyroid Function**
 - Effects of Sulfamethoxazole-Trimethoprim on Thyroid Function
- 5 Hypothyroidism**
 - Secondary Hypothyroidism Following Head Trauma
 - Proliferative Responses to Canine Thyroglobulin in Hypothyroid Dogs
- 7 Hyperthyroidism**
 - Risk Factors for Feline Hyperthyroidism
- 8 Hyperparathyroidism and Hypercalcemia**
 - Primary Hyperparathyroidism in Dogs
 - Pamidronate Disodium for Treatment of Hypercalcemia
- 10 Hypoparathyroidism**
 - Nutritional Calcium Deficiency and Hypoparathyroidism
- 11 Diabetes Mellitus**
 - Transdermal Application of Glipizide to Healthy Cats
- 12 Pancreatic Islet Tumors**
 - Somatostatin Receptor Imaging for the Diagnosis of Canine Insulinoma
 - Comparison of Imaging Techniques for the Detection and Localization of Canine Insulinoma
- 14 Hyperadrenocorticism**
 - Hyperadrenocorticism Caused by Ectopic Secretion of Adrenocorticotropic Hormone
 - Sex Hormones in Dogs with Adrenal Dysfunction
 - Primary Hyperaldosteronism in Cats
 - Pressor Sensitivity to Norepinephrine in Dogs with Iatrogenic Hyperadrenocorticism
- 18 Hypoadrenocorticism**
 - Decreased Sodium:Potassium Ratios in Cats
 - Metastatic Tumors to the Adrenal Glands
 - Spontaneous Hypoadrenocorticism After a Diagnosis of Hyperadrenocorticism
- 21 Gonadal Disorders**
 - Seminoma with Hyperestrogenemia



Plasma Pituitary Prohormones and Pituitary Adenoma Size in Cushing's Disease

Granger N, de Fornel P, Devauchelle P, et al. Plasma pro-opiomelanocortin, pro-adrenocorticotropic hormone, and pituitary adenoma size in dogs with Cushing's disease. *J Vet Intern Med* 2005;19:23-28.

► INTRODUCTION:

Background: Hyperadrenocorticism in dogs is among the three most common endocrinopathies of dogs. Approximately 85% of dogs with spontaneous hyperadrenocorticism have pituitary-dependent hyperadrenocorticism (PDH). Pituitary-dependent hyperadrenocorticism is due to an excessive secretion of adrenocorticotropic hormone (ACTH), usually by a pituitary microadenoma. However, up to 30% of PDH cases have macroadenomas. Medical treatment to suppress adrenocortical function can be effective treatment for PDH caused by microadenomas, but the medical management of PDH from macroadenomas is much less satisfactory. Yet, without computed tomography (CT) or magnetic resonance (MR) imaging, the size of pituitary tumors antemortem can only be speculated. There is preliminary evidence that the ratio of circulating precursors to ACTH (pro-opiomelanocortin and pro-ACTH) may differ between microadenomas and macroadenomas.

Objectives: The purpose of this study was to investigate the relationship between plasma pro-opiomelanocortin (POMC)/pro-ACTH and the size of pituitary tumors in dogs with PDH.

✕ SUMMARY:

Methods: Thirty-six dogs with spontaneous PDH were evaluated. Plasma POMC and pro-ACTH concentrations and pituitary tumor height/brain area were measured in each.

Results: Pituitary tumor size (tumor height/brain area) correlated significantly with plasma

POMC and pro-ACTH. Larger tumors (0.4 X 10⁻²/mm, or more) had greater concentrations of ACTH precursors. At a threshold of 35 pmol of POMC/pro-ACTH concentration, the estimated sensitivity and specificity were 93% and 86%, respectively.

Conclusions: Measurement of plasma POMC and pro-ACTH concentrations may be of value in estimating size of pituitary tumors in dogs with PDH. Low POMC/pro-ACTH concentration is suggestive of a microadenoma.

Low POMC/
pro-ACTH
concentration is
suggestive of a
microadenoma



CLINICAL IMPACT:

Measurement of plasma POMC/pro-ACTH concentration ratio may be of prognostic value in cases of PDH in dogs. Based on the results of this study, if the POMC/pro-ACTH exceeds 35 pmol, greater effort to initially investigate cranial neurological function and to monitor for neurological deficiencies is warranted. This indirect assessment of pituitary size using ACTH precursors in the plasma is not infallible due to the variation in canine skull size and shape and the shape of pituitary tumors. However, if cost effective, it could be an assessment of pituitary size in practices that do not have ready access to CT or MR imaging. At this time, assays for POMC and pro-ACTH are not available for routine clinical use.

- ▶ Plasma pro-opiomelanocortin to pro-ACTH ratio may be helpful in qualitatively assessing the size of pituitary tumors associated with pituitary-dependent hyperadrenocorticism. *J Vet Intern Med* 2005;19:23-28.
- ▶ An α -MSH secreting pituitary adenoma has been found in an insulin-resistant diabetic cat. *Vet Pathol* 2005;42:92-97.
- ▶ An oral dosage of 15 mg/kg of sulfamethoxazole-trimethoprim, twice per day, for two weeks or more will suppress thyroid function in dogs. *Am J Vet Res* 2005;66:256-259.
- ▶ Secondary hypothyroidism and central diabetes insipidus following head trauma has been reported in a cat. *J Fel Med Surg* 2005;7:135-139.
- ▶ Loss of self-tolerance to thyroid antigens in CD4⁺ T cells may be an important part of the pathogenesis of hypothyroidism in dogs. *J Vet Med Sci* 2005;67:363-358.
- ▶ Consumption of commercial canned cat food is associated with an increased risk of hyperthyroidism in cats. *NZ Vet J* 2005;53:53-58.
- ▶ The calcium X phosphate product may not be a useful prognosticator of the risk of renal failure in canine primary hyperparathyroidism. *J Sm Anim Pract* 2005;46:10-16.
- ▶ Pamidronate disodium has been recommended as a safe and effective treatment for hypercalcemia in dogs and cats. *J Vet Intern Med* 2005;19:29-33.
- ▶ Hypocalcemic tetany has been precipitated by deficient nutritional calcium in an older dog with hypoparathyroidism. *Vet Rec* 2005;156:45-48.
- ▶ Short-term transdermal application of glipizide is not a reliable means of affecting blood glucose concentration in healthy cats. *Am J Vet Res* 2005;66:581-588.
- ▶ Somatostatin receptor imaging can facilitate the diagnosis of insulinoma in dogs, but it cannot always localize the primary tumor. *J Vet Intern Med* 2005;19:168-176.
- ▶ Ultrasonography, computed tomography, and single-photon emission computed tomography are helpful in identifying primary insulinoma tumors in dogs, but none are as effective as intra-operative inspection and palpation of the pancreas. *J Vet Intern Med* 2005;19:15-22.
- ▶ Hyperadrenocorticism in a dog has been attributed to ectopic secretion of adrenocorticotrophic hormone from an intra-abdominal tumor in the region of the pancreas. *Dom An Endocrinol* 2005;28:338-348.
- ▶ Dogs with adrenal-dependent hyperadrenocorticism secrete more adrenal sex hormones than dogs with pituitary-dependent hyperadrenocorticism. *J Am Vet Med Assoc* 2005;226:556-561.
- ▶ Primary hyperaldosteronism without adrenal tumor in cats is similar to idiopathic hyperaldosteronism in humans and is associated with progressive renal failure. *Dom Anim Endocrinol* 2005;28:85-104.
- ▶ Iatrogenic hyperadrenocorticism causes increased sensitivity to norepinephrine pressor effects. *Res Vet Sci* 2005;78:25-31.
- ▶ Decreased sodium:potassium ratios occur with diseases other than primary hypoadrenocorticism in cats, particularly effusive processes. *Vet Clin Pathol* 2005;34:110-114.
- ▶ More than 25% of dog and 60% of cat adrenal gland tumors are metastatic tumors to the adrenal glands. *Vet Pathol* 2005;42:52-58.
- ▶ Spontaneous hypoadrenocorticism has been described in a dog after an earlier diagnosis of hyperadrenocorticism. *J Vet Intern Med* 2005;19:255-258.
- ▶ A dog with hyperestrogenemia associated with a seminoma has been reported. *J Vet Med Sci* 2005;67:121-123.



Melanotroph Pituitary Adenoma with Diabetes Mellitus

Meij BP, van der Vlugt-Meijer RH, van den Ingh TSGAM, et al. Melanotroph pituitary adenoma in a cat with diabetes mellitus. *Vet Pathol* 2005;42:92-97.

► INTRODUCTION:

Background: Pituitary-dependent hyperadrenocorticism can be due to corticotropic adenomas of the pars distalis or intermedia. The majority of the cells in the pars intermedia are melanotrophs. Melanotropic adenomas produce melanocyte-stimulating hormone (MSH) which is structurally related to adrenocorticotrophic hormone (ACTH). The extrapituitary signs of melanotrophs in cats have not been reported.

Objectives: The purpose of this report was to describe a cat with insulin-resistant diabetes mellitus and a melanotroph adenoma of the pituitary.

✦ SUMMARY:

Case Report: A 13-year-old, castrated male, cat was evaluated for insulin-resistant diabetes mellitus. Its appetite was increased. The hair coat was dull. The basal urine corticoid-to-creatinine ratios were normal, but there was no suppression to low-dose dexamethasone. Endogenous ACTH concentration, which was not elevated, declined in response to low-dose dexamethasone. Plasma α -MSH concentration was markedly elevated. Plasma growth hormone and insulin-like growth factor were not elevated. Computed tomography (CT) of the head revealed a pituitary tumor believed to be in the pars intermedia.

A hypophysectomy was performed. After the surgery, insulin was not required to maintain euglycemia and clinical signs resolved. Biopsy of the removed tumor verified an adenoma of the pars intermedia. Immunohistochemistry revealed strong staining for α -MSH and weak staining for ACTH.

Conclusions: The cause for pituitary-dependent hyperadrenocorticism in the cat of this report was due to a melanotroph adenoma and the glucocorticotropic effect of excessive MSH.



CLINICAL IMPACT:

Pro-opiomelanocortin (POMC) is a large molecule in the pars distalis and intermedia that is degraded to β -endorphin, ACTH, and MSH.

In the pars distalis, POMC is hydrolyzed to ACTH and β -endorphin. In the pars intermedia, it is hydrolyzed further to α -MSH. Alpha-MSH contains the first 13 amino acid residues of ACTH. A classical and often the earliest sign of primary hyperadrenocorticism in humans is hyperpigmentation due to elevated ACTH concentrations and the MSH it contains in its structure.

The cat of this report indicates that markedly elevated α -MSH concentrations can have weak, but sufficient adrenocorticotrophic effects, to produce clinical signs of hyperadrenocorticism. The form of hyperadrenocorticism was characterized by cortisol production being refractory to dexamethasone suppression while endogenous ACTH was suppressed along with evidence of a pituitary tumor. No mention was made of signs of hyperpigmentation which, if present, could have value in justifying the effort and cost of measuring plasma α -MSH concentration and in attempting to localize a pituitary tumor to the pars intermedia using CT or magnetic resonance imaging.

The cause for pituitary-dependent hyperadrenocorticism was due to the glucocorticotropic effect of excessive MSH



Effects of Sulfamethoxazole-Trimethoprim on Thyroid Function

Frank LA, Hnilica KA, May ER, et al. Effects of sulfamethoxazole-trimethoprim on thyroid function in dogs. *Am J Vet Res* 2005;66:256-259.

► INTRODUCTION:

Background: Potentiated sulfonamides suppress thyroid hormone secretion by inhibiting the activity of thyroid peroxidase and can cause hypothyroidism. Serum thyroid hormone concentrations were suppressed as early as one week of initiating treatment in one study, and clinical signs of hypothyroidism can be seen with more prolonged treatment. This has been considered a dose-dependent characteristic of the drugs, because lower therapeutic doses of trimethoprim-sulfadiazine have been shown to have no effect on thyroid function tests.

Objectives: The objective of this study was to determine if the effect on thyroid function of trimethoprim-sulfamethoxazole at 15 mg/kg twice daily is similar to that noted when twice the dose is administered to healthy dogs.

✕ SUMMARY:

Methods: Six healthy client-owned dogs were administered 15 mg/kg trimethoprim-sulfamethoxazole orally twice per day for three weeks. Blood samples were collected prior to treatment and weekly during treatment and for three weeks after cessation of treatment. Serum concentrations of total T_4 , free T_4 , and canine (c) thyroid-stimulating hormone (TSH) were measured at each time. Schirmer tear tests were conducted weekly, and a complete blood count was evaluated at week 3 of treatment and three weeks after discontinuing treatment.

Results: Serum concentrations of total T_4 and free T_4 were significantly decreased and cTSH was significantly increased at week 3 of treatment compared with concentrations prior to treatment. Serum total T_4 was below the reference range in three dogs and near the lower limit of the reference range in two dogs after three weeks of treatment, and returned to

normal within one week after stopping the trimethoprim-sulfamethoxazole administration. Serum free T_4 was below the reference range in four dogs after three weeks of treatment, and became normal in all dogs after stopping treatment for one week.

Serum cTSH concentration was above the reference range in four dogs after three weeks of antimicrobial administration, and remained elevated in three of these dogs one week after stopping treatment. The serum cTSH was within the reference range in all dogs two and three weeks after cessation of treatment.

There was no significant change in the mean white blood cell count during treatment, although one dog developed neutropenia after three weeks of treatment. The white blood cell count was significantly higher three weeks after cessation of treatment compared with week 3 of treatment. Tear production decreased transiently during treatment in two dogs, returning to normal within three weeks of stopping treatment.

Conclusions: Administration of trimethoprim-sulfamethoxazole at a dosage of 15 mg/kg twice per day suppresses thyroid function in a manner compatible with hypothyroidism.

🌀 CLINICAL IMPACT:

It is unclear why a previous controlled study of the effects of trimethoprim-sulfadiazine administered at the same dose as this study did not result in suppressed thyroid function. The present study lacked a control group, but the decreases in total and free T_4 and elevation of cTSH were consistent and almost certainly due to drug effects. It is possible that sulfadiazine has less effect on thyroid function than sulfamethoxazole, but a higher dose of sulfadiazine suppresses thyroid hormone secretion.

Based on this and previous studies,

thyroid function should not be evaluated while a dog is being treated with any dose of sulfonamide. Discontinuation of treatment for 2-3 weeks is recommended prior to thyroid function testing a dog previously treated with a potentiated sulfonamide.

Thyroid function should not be evaluated while a dog is being treated with any dose of sulfonamide



Secondary Hypothyroidism Following Head Trauma

Mellanby RJ, Jeffery ND, Gopal MS, et al. Secondary hypothyroidism following head trauma in a cat. *J Fel Med Surg* 2005;7:135-139.

► INTRODUCTION:

Background: Hypothyroidism is rare in cats. Secondary hypothyroidism is rare in all species. However, head trauma is relatively common in dogs and cats with most cases due to being struck by motorized vehicles. Head trauma can cause hypothalamic and hypophyseal damage and lead to secondary hypothyroidism, among other manifestations of neurologic and endocrinologic dysfunction.

Objectives: The reason for this case report was to describe a young cat with secondary hypothyroidism resulting from cranial trauma at eight weeks of age.

✕ SUMMARY:

Case Report: A 12-year-old, spayed female cat was presented with polydipsia and stunted growth and normal proportions. Polydipsia had been present since the cat was 8-weeks-old after a cupboard door fell on its head. Urinalysis revealed hyposthenuria (specific gravity of 1.007). Magnetic resonance imaging (MRI) of the head disclosed an almost empty sella turcica. Central diabetes insipidus was tentatively diagnosed, and the cat was treated with desmopressin by conjunctival drops with partially successful results on the control of hyposthenuria. Dentition was delayed, the hemogram was normal, and serum biochemistries included elevated glucose, urea, creatinine, phosphorus, creatine kinase, and calcium concentrations. Serum adrenocorticotropic hormone (ACTH) and insulin-like growth factor I (IGF-I) concentrations were normal, T₄ was low, and endogenous thyroid-stimulating hormone (TSH) was undetectably low. Plasma cortisol concentration was low but responsive to ACTH stimulation. Thyrotropin-releasing

hormone (TRH) was ineffective in raising T₄ or TSH serum concentrations. Radiographs of the tibiae demonstrated open epiphyseal plates. Re-examination approximately one month later revealed essentially the

same laboratory findings plus a low serum free T₄ concentration and insignificant levels of autoantibodies to T₃ and T₄. Desmopressin administration was recommended to be continued, and replacement doses of thyroxine were prescribed.

Conclusions: This was proposed to be the first report of secondary hypothyroidism in a cat following head trauma.

There was no mention in this report of the cat's response to thyroxine administration

🌀 CLINICAL IMPACT:

Unfortunately, there was no mention in this report of the cat's response to the very high dose of thyroxine administration (0.25 mg, twice per day: enough for a 25-50 lb dog). So, the diagnosis of secondary hypothyroidism remains unconfirmed. The other criteria for the diagnosis were insufficient for a definitive diagnosis, i.e. low serum T₄ and free T₄, low TSH, poor response to TRH stimulation, and MRI finding of an apparent empty sella turcica.

Low serum T₄ and free T₄ can occur with primary or secondary hypothyroidism and with euthyroid sick syndrome. The endogenous TSH assay used on the cat of this report before and after TRH administration was an anti-canine TSH assay, an insensitive evaluation even in the dog. An image of an apparent empty sella turcica does not confirm an insufficiency of TSH, and when pituitary destruction leads to TSH deficiency it is preceded by growth hormone deficiency. IGF-1 concentration was normal, inconsis-

tent with a growth hormone deficiency.

The stunting of growth caused by neonatal or juvenile hypothyroidism is disproportionate (long body, big head, short legs, short mandible). This cat was proportionately small. Hypothyroidism impairs red blood cell production. Thyroid hormone deficiency of the magnitude to impair closure of growth plates would be accompanied by normochromic, normocytic anemia which was not present in the cat of this report. Delayed epiphyseal ossification was said to be present, but epiphyseal dysplasia, a pathognomic finding in congenital hypothyroidism, was not evident in the tibial radiographs shown in the report.

Despite the findings in this cat that were atypical of secondary hypothyroidism, documenting a complete reversal of all abnormal findings after the replacement of thyroid hormone at physiologic doses would have confirmed a diagnosis of hypothyroidism, possibly secondary in origin. This was not provided in the report.



Proliferative Responses to Canine Thyroglobulin in Hypothyroid Dogs

Tani H, Nabetani T, Sasai K, et al. Proliferative responses to canine thyroglobulin of peripheral blood mononuclear cells from hypothyroid dogs. *J Vet Med Sci* 2005;67:363-358.

► INTRODUCTION:

Background: Hypothyroidism in dogs is generally caused by an autoimmune disease process resulting in lymphocytic thyroiditis. It is also characterized by the presence of circulating antibodies to thyroglobulin, the predominant protein in the colloid of thyroid follicles. The pathogenic mechanisms of the immune response in autoimmune thyroiditis in dogs has not been characterized, but cell-mediated immunity is the primary mechanism for thyroid gland destruction in humans with autoimmune thyroiditis.

Objectives: The objective of this study was to determine the role of T lymphocytes in the pathogenesis of autoimmune hypothyroidism.

✕ SUMMARY:

Methods: The response of peripheral blood mononuclear cells to thyroglobulin were evaluated in three dogs with hypothyroidism with autoantibodies to thyroglobulin and in three normal dogs. Lymphocytes isolated from whole blood were tested for their proliferative response to incubation with canine thyroglobulin. A positive control was provided by incubation with concanavalin A, and the negative control was tissue culture medium. After incubation, a stimulation index was calculated to represent the proliferation in response to thyroglobulin. The lymphocyte subpopulations were evaluated by labeling with antibodies to Thy-1, CD4, CD8, and IgG.

Results: The lymphocyte proliferative response to thyroglobulin was higher in two of the three hypothyroid dogs compared with the control dogs. The number of CD4⁺ cells increased significantly in hypothyroid dogs in the presence of thyroglobulin. There was a tendency for cells positive for CD8 and IgG to increase in response to thyroglobulin. Thy-1 express-

ing cells did not increase when incubated with thyroglobulin.

Conclusions: Abnormalities in cell mediated immunity, perhaps involving CD4⁺ cells (helper T cells) are involved in the pathogenesis of autoimmune thyroiditis in dogs.

Abnormalities in cell mediated immunity are involved in the pathogenesis of autoimmune thyroiditis in dogs



CLINICAL IMPACT:

In humans, a combination of genetic and environmental factors influence loss of self tolerance and development of autoimmune diseases, including thyroiditis. The suggestion from this canine study that CD4⁺ cells may be mediators of autoimmune thyroiditis is similar to the disease in humans. While the clinical significance of these early findings is minimal, it is possible that further study could result in tests that could identify dogs at risk for development of thyroiditis or perhaps guide specific therapy to prevent hypothyroidism in patients with thyroiditis.



Risk Factors for Feline Hyperthyroidism

Olczak J, Jones BR, Pfeiffer DU, et al. Multivariate analysis of risk factors for feline hyperthyroidism in New Zealand. NZ Vet J 2004;53:53-58.

► INTRODUCTION:

Background: Hyperthyroidism is the most frequently diagnosed endocrinopathy in the cat. The most common lesion is multinodular adenomas in both thyroid lobes. The cause is unknown, but several risk factors have been identified in a small number of reports.

Objectives: The aim of this report was to search for possible risk factors for feline hyperthyroidism.

✕ SUMMARY:

Methods: A questionnaire study was performed by the owners of 375 cats: 125 hyperthyroid, 125 randomly selected controls, and 125 age- and sex-matched controls. The questionnaire was designed to collect data on owner demographics, cats' medical history, cats' indoor and outdoor environment, and diet of the cats.

Results: Hyperthyroid cats were more often female and older than control cats. Domestic short-haired and long-haired cats were at a higher risk for hyperthyroidism than purebreds. Being a single cat in a household was also a risk factor. Hyperthyroid cats were reported to sleep on the floor 6.6 times more often than control cats. Risk also increased if the cat's bedding was regularly treated with flea control products. Cats that drank from puddles in households that used organic garden fertilizers had a 5.3-fold increased risk of hyperthyroidism. If at least half the cat's diet was commercial canned food, the risk of hyperthyroidism was doubled. Cats that ate a variety of canned cat food flavors were more likely to develop hyperthyroidism than cats that ate a single flavor of canned food. Dental disease was associated with a 5.5-fold increase in hyperthyroidism.

Conclusions: This study's findings support the identified risk factors for hyperthyroidism in other studies, plus it showed that female cats may be predisposed to hyperthyroidism.



CLINICAL IMPACT:

No single risk factor emerged that might suggest one cause for initiation of hyperthyroidism. However, some identified risk factors may be related. For example, cats that have a diet of at least 50% commercial canned food may be more likely to live in a single cat household, have dental disease, and have bedding that is regularly treated for fleas. Some factors, such as laying on the floor to seek relief from heat intolerance, drinking water from puddles, and having diarrhea, may have been consequences of hyperthyroidism rather than predisposing factors. Some flavors of canned cat food, particularly fish and organ meats, have iodine concentrations far in excess of recommended daily allowances. In humans, high dietary iodine can induce hyperthyroidism in certain individuals, especially if following a period of iodine deficiency as occurred just after World War II. A similar trigger may occur in a subset of predisposed cats on a variety of canned cat food flavors. Long-term prospective studies are needed to more critically assess the true role of identified risk factors from questionnaire epidemiologic studies.

Female cats may be predisposed to hyperthyroidism



Primary Hyperparathyroidism in Dogs

Gear RNA, Neiger R, Skelly BJS, et al. Primary hyperparathyroidism in 29 dogs: diagnosis, treatment, outcome and associated renal failure. *J Sm Anim Pract* 2005;46:10-16.

► INTRODUCTION:

Background: Primary hyperparathyroidism is diagnosed by documenting hypercalcemia in a dog with a relative and inappropriate elevation of serum parathyroid hormone (PTH) concentration. While polyuria and polydipsia are common clinical signs of this disease, they are usually the result of hypercalcemic effects on renal tubular function rather than primary renal failure.

In fact, renal failure appears to be a relatively uncommon complication of primary hyperparathyroidism despite the frequently prolonged duration of moderate to severe hypercalcemia associated with this disease.

Objectives: The goals of this retrospective study were to describe clinical characteristics of primary hyperparathyroidism and to evaluate correlation between any clinical factor and the presence of renal failure.

✕ SUMMARY:

Methods: Medical records of 29 dogs with primary hyperparathyroidism were reviewed. Criteria for the diagnosis of primary hyperparathyroidism included hypercalcemia with an elevated serum PTH concentration without azotemia, parathyroid gland hyperplasia, or nonparathyroid neoplasia.

Results: Of the 29 affected dogs, there were four Keeshonden and four German shepherd dogs. The median age was 9.3 years. Twenty-three dogs had clinical signs for more than three months. The most common historical complaints were polyuria, polydipsia, and lethargy with stiffness. Gastrointestinal disturbances, weight loss, tremors, and dysuria occurred less frequently. No consistent abnormalities were noted on physical examination. Total and ionized calcium concentrations were elevated

Dogs with renal failure had a significantly higher total calcium concentration preoperatively

in all dogs. Serum phosphate concentration was below the reference range in 14, normal in 12, and elevated in three dogs. Serum alkaline phosphatase activity was elevated in 13, urea was elevated in 13, and cholesterol was elevated in 11 dogs. Serum PTH concentration exceeded the reference range in 25 of the 26 dogs in which it was measured, and was near the upper limit in the remaining dog. Urine specific gravity was less than 1.025 in all 16 dogs that were tested, and bacteria were cultured from five of 11 urine samples.

A nodule consistent with an enlarged parathyroid gland was noted on cervical ultrasound in 26 of 27 dogs tested. Urinary tract calculi were identified in the kidneys of two dogs and bladder of one dog. One dog had pathologic fractures of multiple long bones. Two dogs were euthanized due to acute renal failure that failed to respond to supportive treatment prior to any specific treatment of the primary hyperparathyroidism.

Treatment of primary hyperparathyroidism consisted of surgical parathyroidectomy in 19 cases and attempted ethanol chemical ablation in five dogs. Ethanol injection into the parathyroid nodule using ultrasound guidance resulted in a decrease in ionized calcium in five dogs but continued elevation in two dogs and no effect on total serum calcium in the remaining three dogs. Thirteen of the dogs that underwent surgical parathyroidectomy were administered vitamin D with or without supplemental calcium. The total or ionized serum calcium concentration became normal one to six days after surgery in the 17 dogs in which results were available. Hypocalcemia occurred postoperatively in seven dogs. The preoperative total calcium concentration was significantly higher in the dogs that developed postoperative hypocalcemia than those that remained normocalcemic after surgery. Parathyroid gland adenoma, hyperplasia, or

adenocarcinoma were diagnosed on histopathology in 14, three, and two cases, respectively. Renal failure was diagnosed in seven dogs postoperatively. Four of these had renal failure identified prior to surgery. Dogs with renal failure had a significantly higher total calcium concentration preoperatively than those that did not have renal failure. Concurrent thyroid carcinoma and hyperadrenocorticism were identified in two dogs. Recurrence of hypercalcemia developed in two dogs, and two died of renal failure during the follow-up period.

Conclusions: Dogs with primary hyperparathyroidism with a very high total calcium concentration are at increased risk for developing renal failure.

CLINICAL IMPACT:

The diagnosis of primary hyperparathyroidism relies on finding an inappropriately high serum PTH in the presence of hypercalcemia. While cervical ultrasound examination identified a parathyroid mass in nearly all cases, it was not necessary for the diagnosis. However, it is not unusual to have a dog suspected of primary hyperparathyroidism with a normal serum PTH concentration, and cervical ultrasound can be useful in this setting. Renal function is difficult to assess in the presence of hypercalcemia because urine concentrating ability is impaired. The finding of renal failure in nine of the 29 dogs of this study and the correlation with high calcium levels may indicate that more aggressive and earlier treatment would be beneficial.



Pamidronate Disodium for Treatment of Hypercalcemia

Hostutler RA, Chew DJ, Jaeger JQ, et al. Uses and effectiveness of pamidronate disodium for treatment of dogs and cats with hypercalcemia. *J Vet Intern Med* 2005;19:29-33.

► INTRODUCTION:

Background: Treatment of most cases of hypercalcemia is effectively accomplished by correction of the primary disease process, intravenous fluid therapy, or, in some cases, administration of furosemide or glucocorticoids. Treatment options for hypercalcemia resistant to this therapy includes calcitonin, mithramycin, and bisphosphonates. Pamidronate is a bisphosphonate that acts by inhibiting mineral reabsorption from bone.

Objectives: This study was conducted to evaluate the response to administration of pamidronate to dogs and cats with hypercalcemia of various etiologies.

✦ SUMMARY:

Methods: Records of seven dogs and two cats with hypercalcemia that were administered pamidronate were reviewed retrospectively. Causes of hypercalcemia in dogs included calcipotriene toxicity in three, lymphosarcoma in two, thyroid carcinoma in one, and multiple endocrine neoplasia in one. One cat had nocardiosis and the other had idiopathic hypercalcemia. All animals had received at least one treatment for hypercalcemia without resolution of the problem. Hypercalcemia was documented to be present for 24 hours to nine months (median six days) prior to pamidronate treatment. The highest total serum calcium concentration ranged from 12.8 to 18.7 mg/dl in the dogs and 12.8 to 18.5 mg/dl in the cats. Ionized serum calcium (normal range 5.0-6.1 mg/dl) measured in four dogs and both cats ranged from 6.24 to 7.96 and 6.33 to 8.72, respectively. The range of doses for pamidronate was 1.05 to 1.7 mg/kg in dogs and 1.5 to 2 mg/kg in cats.

Results: A reduction in serum calcium concentration as noted in all animals within 24 hours and was normal in all but one dog with

lymphoma 48 hours after pamidronate infusion. Initial serum total and ionized calcium and the magnitude of decrease in response to treatment were linearly correlated. The duration of effect of pamidronate in the six animals

Pamidronate is a safe and effective, albeit very expensive, treatment of hypercalcemia

that were not euthanized because of the primary disease was 11 days to nine weeks (median 8.5 weeks) in four animals, while in two dogs the hypercalcemia did not recur. One dog with lymphoma received three doses of pamidronate and another dog with calcipotriene toxicity received two doses. While no adverse effects of pamidronate resulted in clinical deterioration, marked thrombocytopenia developed in one dog with lymphoma that was thought to be a consequence of the primary disease, and low total but normal ionized calcium concentration was noted in the cat with idiopathic hypercalcemia.

Conclusions: Pamidronate is an effective and safe treatment for hypercalcemia of various causes in dogs and cats.

🌀 CLINICAL IMPACT:

Pamidronate is a safe and effective, albeit very expensive, treatment of hypercalcemia. It must be administered by intravenous infusion, but has a prolonged effect after a single treatment that may make it cost-effective. Its use should be reserved for cases that are not responsive to more standard treatments. Oral bisphosphonates are currently used in humans, and may be useful if evaluated in dogs and cats.



Nutritional Calcium Deficiency and Hypoparathyroidism

Diquelou A, Chaput C, Benoit E, et al. Hypocalcaemia due to nutritional calcium deficiency and hypoparathyroidism in an adult dog. Vet Rec 2005;156:45-48.

► INTRODUCTION:

Background: There are many causes of hypocalcemia in dogs. Just one, primary hypoparathyroidism, is associated with low serum parathyroid hormone concentration. The most common cause for hypoparathyroidism is lymphocytic parathyroiditis which typically occurs in mid-aged female dogs. Diet does not cause nor negate the hypocalcemia of primary hypoparathyroidism if moderate to severe deficiency of parathyroid hormone exists.

Objectives: The purpose of this report was to describe a dog with hypocalcemia caused by concurrent hypoparathyroidism and dietary deficiency in calcium.

✕ SUMMARY:

Case Report: A 13-year-old, male, poodle was presented with a history of short periods of abnormal stiff gait and moderate pain in the abdomen. Physical findings included anorexia, listlessness, cachexia, and mild dehydration. During hospital observation, episodes of hyperflexion of the hind legs and hyperextension of the fore legs were noted, plus temporary blindness, behavior changes, and lost consciousness. Laboratory findings were hypocalcemia (0.99 mmol/L, normal: 2.4-3.0 mmol/L) and low parathyroid hormone concentration (12 ng/L, normal: 20-80 ng/L). A good clinical response resulted from intravenous fluid infusion which included calcium gluconate.

The usual diet for the dog was homemade, consisting of chicken, rice, and bouillon and was found to be energy and calcium deficient. Commercial dog food and calcitriol were prescribed and administered. Within four days the serum calcium had risen to normal range. Calcitriol administration was discontinued, and the dog was discharged on commercial

dog food plus oral calcium supplementation.

During the following year, the dog's condition improved. Plasma calcium concentration remained abnormally low (1.98-2.1 mmol/L) as did parathyroid hormone concentration (14 ng/L). Soon after (14 months from presentation) three episodes of tetany followed two days of poor appetite. Oral supplements of vitamin D2 were added to the oral calcium supplements with good clinical response and low normal plasma calcium concentration.

Conclusions: This was the first report of a dog with hypoparathyroidism and low dietary calcium contributing to the clinical signs of hypocalcemia.

🌀 CLINICAL IMPACT:

This dog was described as a subclinical case of hypoparathyroidism which required low dietary calcium to precipitate clinical signs of hypocalcemia. Parathyroid hormone insufficiency precedes deficiency, so a stage in which low dietary calcium could prematurely precipitate clinical signs of hypocalcemia is part of any form of hypoparathyroidism. Most cases of hypoparathyroidism in dogs are due to unremitting lymphocytic parathyroiditis. Although a dietary deficiency or imbalance of calcium can precipitate clinical signs in the early stages of primary hypoparathyroidism, this phase is short-lived with parathyroid hormone deficiency and persistent hypocalcemia occurring soon afterwards. The cause for low plasma parathyroid hormone concentrations which remained static without leading to deficiency in this dog was not determined, but the cause had to be rare in comparison to lymphocytic parathyroiditis.

Most cases of hypoparathyroidism in dogs are due to unremitting lymphocytic parathyroiditis



Transdermal Application of Glipizide to Healthy Cats

Bennett N, Papich MG, Hoenig M, et al. Evaluation of transdermal application of glipizide in a pluronic lecithin gel to healthy cats. *Am J Vet Res* 2005;66:581-588.

► INTRODUCTION:

Background: Glipizide has been used successfully for temporary management of early insulin-independent diabetes mellitus in cats. As an oral sulfonylurea drug, glipizide increases insulin secretion from the pancreas and improves insulin sensitivity in responsive tissues. Because many cat owners find compliance with oral medication difficult, a number of medications have been compounded into preparations that purportedly allow transdermal delivery of drug.

Objectives: The goals of this study were to determine if glipizide was absorbed transdermally, the pharmacokinetics of glipizide after oral and transdermal administration, and the pharmacodynamics of the drug with respect to insulin and glucose concentrations.

✕ SUMMARY:

Methods: Fifteen healthy cats were studied by measurement of glipizide, insulin, and glucose concentrations for 24 hours after administration of a single dose of glipizide orally or in a transdermal preparation, or an oral or transdermal placebo. Four cats were administered 5 mg of glipizide orally, five cats were given 5 mg glipizide compounded into a pluronic lecithin organogel (PLO) transdermally on the inner pinna, three cats were administered placebo orally, and three cats were administered transdermal gel without glipizide.

Results: Plasma glipizide concentrations in the transdermal treatment group were approximately 20% those of the oral treatment group. The peak plasma glipizide concentration in the oral group occurred five hours after administration, while it did not occur until 16 hours after administration in the transdermal group. Marked variation in plasma glipizide concentrations were present in cats in both treatment groups. A significant decrease in

plasma glucose concentration of similar magnitude was noted in all cats treated with glipizide, but the decrease occurred earlier in the oral treatment group compared with that of the transdermal treatment group. Plasma insulin concentrations did not change significantly during the study in any treatment group.

Conclusions: Transdermal administration of glipizide cannot be recommended for clinical use at this time as it is absorbed inconsistently and to a lesser extent than when administered orally.

Transdermal administration of glipizide cannot be recommended for clinical use at this time



CLINICAL IMPACT:

When administered orally, glipizide has been reported to control the clinical signs and blood glucose concentrations of approximately 25% of diabetic cats. One reason for the limited efficacy of the drug may be the variable absorption that occurs even when administered by mouth. While absorption of the transdermal glipizide preparation was reduced compared with the oral route, all cats had detectable drug in the plasma.

It is quite possible that repeated administration of the drug in the PLO gel will ultimately increase the absorption of glipizide. For example, a single transdermal application of methimazole results in inconsistent and minimal absorption, whereas chronic administration has a good therapeutic effect. It is unclear why plasma insulin did not increase after glipizide administration in this study since a previous study demonstrated that insulin secretion was enhanced by glipizide. It is possible that glipizide substantially increases insulin sensitivity in responsive tissues and has a useful effect in the absence of enhanced insulin secretion in the cat.



Somatostatin Receptor Imaging for the Diagnosis of Canine Insulinoma

Garden OA, Reubi JC, Dykes NL, et al. Somatostatin receptor imaging in vivo by planar scintigraphy facilitates the diagnosis of canine insulinomas. *J Vet Intern Med* 2005;19:168-176.

► INTRODUCTION:

Background: Indium (^{111}In) pentetreotide scintigraphy is effective in imaging somatostatin receptors in some islet cell tumors. The imaging technique in humans is often successful for imaging gastrinomas but not useful for localizing insulinomas. The degree of association of somatostatin receptors with insulinomas in dogs is unknown.

Objectives: The aim of this study was to describe the clinicopathologic, imaging, and scintigraphic findings in five dogs with insulinomas.

✕ SUMMARY:

Methods: Indium (^{111}In) pentetreotide scintigraphy was performed on five dogs with insulinomas. The diagnosis was based on clinical signs of hypoglycemia, the presence of blood glucose concentration of less than 60 mg/dl, inappropriate hyperinsulinemia of more than 20 $\mu\text{IU/ml}$, and histologic examination of excised tumor tissue. Scintigrams were obtained in each dog at 1, 4, 12, and 24 hours after intravenous injection of the radioactive tumor marker.

Results: Somatostatin receptors were detected by scintigraphy unequivocally in four dogs and equivocally in one dog. The location of a primary tumor was evident in just one of the five dogs.

Conclusions: Pancreatic scintigraphy with ^{111}In -pentetreotide can aid the diagnosis of insulinomas in dogs, but it cannot usually assist in locating the tumor within the pancreas.



CLINICAL IMPACT:

Scintigraphy using a somatostatin marker is unnecessary for a clinical diagnosis of insulinoma. Determination of fasting plasma glucose and insulin and calculation of an insulin-to-glucose ratio is safer, less expensive, and more diagnostically sensitive than scintigraphy for insulinoma. Somatostatin scintigraphy is also not reliable in localizing the primary site of most insulinomas, and it may detect tumors other than insulinomas, confounding the diagnosis and proper therapeutic approach. Perhaps, more specific radioactive markers than somatostatin receptors will yield more useful results.

Pancreatic scintigraphy with ^{111}In -pentetreotide cannot usually assist in locating the tumor within the pancreas



Comparison of Imaging Techniques for the Detection and Localization of Canine Insulinoma

Robben JH, Pollak YWEA, Kirpensteijn J, et al. Comparison of ultrasonography, computed tomography, and single-photon emission computed tomography for the detection and localization of canine insulinoma. *J Vet Intern Med* 2005;19:15-22.

► INTRODUCTION:

Background: Insulinomas are usually malignant in the dog and gross metastasis is identified in approximately 50% of cases at the time of diagnosis. Because surgery is the most effective treatment, accurate preoperative identification of the primary pancreatic lesion and any metastasis would be useful in planning surgery and in prognostication. Somatostatin receptor scintigraphy is a method whereby cells containing somatostatin receptors (such as insulinoma cells) are labeled by a radioactive tracer.

Objectives: This study was performed to compare the accuracy of abdominal ultrasound, computed tomography (CT), and somatostatin receptor scintigraphy for localization of insulinoma in dogs.

✕ SUMMARY:

Methods: Thirteen dogs with a diagnosis of insulinoma based on clinical signs of hypoglycemia, hypoglycemia on repeated measurements, and an inappropriately elevated plasma insulin concentration in the presence of hypoglycemia underwent abdominal ultrasonography, CT, and somatostatin receptor analog scintigraphy. Accuracy of these results was determined by comparison of the findings of these tests with identification of the insulinoma in left and right limbs and body of the pancreas, lymph nodes, or liver at surgery or necropsy.

Results: Insulinoma was identified at surgery or necropsy as a solitary pancreatic mass in 12 dogs, while one dog had two pancreatic tumors. Lymph node metastasis was present in five dogs, and hepatic metastasis was found in four dogs, including three with lymph node metastasis.

Intraoperative inspection and palpation of the pancreas is more effective than any of the imaging techniques in detecting insulinomas

The image quality on abdominal ultrasonography was poor in nine dogs. Only part of the pancreas could be identified in 12 dogs.

The pancreas was not visualized in the remaining dog. The tumor in the pancreas was visualized, and the location was correctly identified in five dogs. The wrong area of the pancreas was identified in two, and not seen at all in six dogs. Enlarged lymph nodes consistent with metastasis were not identified in the proper location in any of the five dogs with metastasis. Liver metastases were visualized in one of the four dogs. One dog without hepatic metastasis was stated to have a solitary metastatic lesion in the liver.

Using CT, pancreatic neoplasia was correctly identified in 10 dogs with insulinoma. All lymph nodes draining the pancreas that were visible were considered enlarged and consistent with metastatic disease. This resulted in identification of 30 lymph nodes with suspected metastasis. Only two of the five dogs with true lymph node metastasis had proper identification of the lesions. False positive results for lymph node metastasis occurred in nine dogs. Liver metastasis was properly diagnosed in two of four positive dogs on CT. One dog without a metastatic lesion had a lesion consistent with metastasis noted.

Scintigraphy was positive in six dogs for pancreatic masses. None of the five dogs with lymph node metastasis had these lesions identified on scintigraphy. Two of the dogs with hepatic metastasis had metastatic lesions identified using scintigraphy.

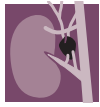Conclusions: Intraoperative inspection and palpation of the pancreas is more effective than any of the imaging techniques, and scintigraphy is as effective as ultrasound and CT in detecting insulinomas.



CLINICAL IMPACT:

The diagnosis of insulinoma can be made without identifying a pancreatic mass. The primary rationale of imagining is to stage the neoplasm and to aid the surgeon in locating the primary and metastatic lesions. The prognosis in dogs with visible metastasis at the time of surgery is considerably worse than in dogs without gross metastatic disease.

None of the imaging techniques described in this paper has sufficient accuracy to be reliable when making a decision regarding prognosis prior to surgery. Because hepatic nodular regeneration is common in aged dogs and can mimic metastatic neoplasia, caution must be exercised when interpreting hepatic masses found on all imaging techniques. Similarly, lymph node enlargement can lead to a false assumption of metastasis on CT and less frequently, abdominal ultrasound.



Hyperadrenocorticism Caused by Ectopic Secretion of Adrenocorticotrophic Hormone

Galac S, Kooistra HS, Voorhout G, et al. Hyperadrenocorticism in a dog due to ectopic secretion of adrenocorticotrophic hormone. *Dom An Endocrinol* 2005;28:338-348.

► INTRODUCTION:

Background: Spontaneous hyperadrenocorticism in dogs is traditionally categorized as either pituitary-dependent or adrenal-dependent in origin. However, malignant tumors or rarely benign tumors outside the hypothalamic-pituitary-adrenal axis have the potential to synthesize biologically active forms of adrenocorticotrophic hormone (ACTH). This ectopic ACTH syndrome comprises 15 to 20% of the cases of ACTH-dependent hyperadrenocorticism in humans.

Most are caused by small-cell carcinomas of the lung. Most cases occur in males and the onset of hyperadrenocorticism is rapid, often devoid of clinical signs that require prolonged exposure to glucocorticoid excess to develop. A well described case of ectopic hyperadrenocorticism has not been reported in the dog.

Objectives: The purpose of this case report was to describe a dog with presurgical findings consistent with pituitary-dependent hyperadrenocorticism but did not respond to hypophysectomy.

✕ SUMMARY:

Case Report: An 8-year-old, male, German shepherd dog was presented with polyuria, polydipsia, polyphagia, and excessive panting. The hair coat was clinically normal. Physical activity was normal. Hepatomegaly was detected by abdominal palpation. Laboratory findings included a mild elevation of alkaline phosphatase activity and hypokalemia. Urine specific gravity was low (1.008). Basal urine corticoid/creatinine ratio was abnormally high on two consecutive days. The cortisol production was refractory to dexamethasone suppression. Endogenous ACTH concentra-

tions were 159 and 188 ng/L (normal upper limit of 85 ng/L). Abdominal ultrasonography was consistent with bilateral adrenal enlargement. Dynamic computerized tomography (CT) revealed no pituitary enlargement or displacement.

The diagnosis was a probable microadenoma of the pituitary causing pituitary-dependent hyperadrenocorticism.

Hypophysectomy was performed. Microscopic examination of the removed tissue did not reveal any tumor.

Immunohistochemical staining for ACTH was negative. Two weeks after surgery, the dog's clinical signs had worsened. Hair that was clipped for surgery showed no evidence of regrowth.

Hypokalemia and elevated serum alkaline phosphatase activity had also become worse. The urine specific gravity was hyposthenuric despite the post-surgical administration of desmopressin. Urine corticoid/creatinine ratio was extremely high, as was plasma ACTH (281 ng/L). Administration of corticotropin-releasing hormone did not alter the ACTH concentration. CT of the pituitary showed no pituitary tissue. A diagnosis of ectopic hyperadrenocorticism was suspected.

Total body CT revealed a small mass (2.6 X 3.3 cm) in the region of the left lobe of the pancreas and three hypodense lesions in the liver. During a laparotomy, additional tumors were found in the liver. A partial pancreatectomy was performed. There was no ACTH immunostaining in the removed tumor tissue. Histologic examination revealed a neuroendocrine tumor. Plasma ACTH and cortisol did not decline after pancreatectomy. Trilostane was administered with good results. The dog remained on trilostane and was in good condition 18 months later, but nodules of metastasis persisted in the liver based on ultrasonography.

Conclusions: This was the first well-documented case of ectopic ACTH syndrome in the dog.

🌀 CLINICAL IMPACT:

This was an excellent description of ectopic ACTH syndrome. The vast majority of dogs with ACTH-dependent hyperadrenocorticism do not have pituitary imaging done and are treated medically as pituitary-dependent. As a result, many cases of ectopic ACTH syndrome may have been misdiagnosed as pituitary-dependent. It is very likely that the incidence of ectopic ACTH syndrome in dogs is significant. Ectopic ACTH syndrome should be suspected in any dog with a malignant tumor outside the pituitary and ACTH-dependent hyperadrenocorticism.

Many cases of ectopic ACTH syndrome may have been misdiagnosed as pituitary-dependent



Sex Hormones in Dogs with Adrenal Dysfunction

Hill KE, Scott-Moncrieff CR, Koshko MA, et al. Secretion of sex hormones in dogs with adrenal dysfunction. *J Am Vet Med Assoc* 2005;226-556-561.

► INTRODUCTION:

Background: The sensitivity of the adrenocorticotropic hormone (ACTH) response test for diagnosis of hyperadrenocorticism in dogs is lower than that of the low-dose dexamethasone suppression test, particularly in dogs with adrenocortical neoplasia. However, the low-dose dexamethasone suppression test has lower specificity than the ACTH response test in dogs with non-adrenal illness. Measurement of sex hormones derived from the adrenal gland has been shown to be useful in diagnosis of pituitary-dependent hyperadrenocorticism (PDH) and in a few dogs with hyperadrenocorticism due to adrenocortical neoplasia that do not have exaggerated cortisol secretion in response to ACTH.

Objectives: The objectives of this study were to determine if measurement of sex hormones is useful in the diagnosis of hyperadrenocorticism and if dogs with adrenal tumors have higher sex hormone concentrations than dogs with PDH.

✕ SUMMARY:

Methods: Serum concentrations of cortisol, androstenedione, estradiol, progesterone, 17-hydroxyprogesterone, and testosterone were measured before and one hour after ACTH administration in 11 normal dogs, 11 dogs with PDH, nine dogs with hyperadrenocorticism due to an adrenal tumor (ADH), and six dogs with noncortisol-secreting adrenal tumors. Of the nine dogs with adrenocortical tumors causing hyperadrenocorticism, seven were found to be adenocarcinoma on histopathology or invasion of the caudal vena cava, and two were not classified as they were small, noninvasive masses on ultrasound and not evaluated histologically. Dogs were determined to have ADH when there was

no suppression of cortisol during a low-dose dexamethasone suppression test, low endogenous ACTH concentration, and a unilateral adrenal mass present on abdominal ultrasound. Dogs that had clinical signs, cortisol concentrations on ACTH response test, and low-dose dexamethasone suppression test results that were not consistent with hyperadrenocorticism but had a unilateral adrenal mass on abdominal ultrasound, were placed in the noncortisol-secreting adrenal tumor group.

Results: Histopathology of adrenal masses was performed in four of the six dogs with nonfunctional tumors. Pheochromocytoma was diagnosed in three, and a nonfunctional adenocarcinoma was present in the fourth dog. The remaining two dogs in the nonfunctional tumor group were presumed to have pheochromocytoma based on the presence of hypertension, an adrenal mass, and no evidence of hyperadrenocorticism.

Basal concentrations of cortisol and sex steroid hormones were variable. The most consistent finding was elevated androstenedione in all seven dogs with adrenocortical adenocarcinomas. Post-ACTH cortisol concentrations were elevated in 10 of 11 dogs with PDH, six of seven dogs with adenocarcinoma, and one of six dogs with a noncortisol-secreting tumor. The dog with the noncortisol-secreting tumor and an elevated cortisol had normal suppression of cortisol on a low-dose dexamethasone suppression test, and a pheochromocytoma without other adrenal pathology was found on necropsy.

Androstenedione was elevated after ACTH administration in six of seven dogs with functional adrenocortical carcinoma, eight of 10 dogs with PDH, and four of six dogs with noncortisol-secreting adrenal tumors. Progesterone concentrations were elevated

after ACTH administration in all seven dogs with adenocarcinoma, eight of 10 dogs with PDH, one of the two dogs with an unclassified adrenal tumor, and one of six dogs with a noncortisol-secreting tumor. The mean progesterone concentration in dogs with adenocarcinoma was significantly greater than that of all three other groups. Serum 17-hydroxyprogesterone concentrations were elevated in six of seven dogs with adenocarcinoma, nine of 11 with PDH, four of six with noncortisol-secreting tumors, and both dogs with unclassified adrenal tumors. The mean 17-hydroxyprogesterone was significantly higher in dogs with adenocarcinomas than the other groups. Testosterone was elevated in only two dogs with adenocarcinoma. Estradiol was within the reference range in all dogs tested.

Conclusions: Dogs with adrenocortical adenocarcinomas have serum concentrations of sex steroids that increase in response to ACTH more than dogs with PDH or non-cortisol secreting adrenal tumors.

🌐 CLINICAL IMPACT:

The sensitivity of the ACTH response test for diagnosis of hyperadrenocorticism is increased by measurement of adrenal sex hormones, as most dogs with PDH or hyperadrenocorticism due to adrenal adenocarcinoma have elevation of one or more sex hormones. However, four dogs with adrenal tumors and no evidence of hyperadrenocorticism had elevation of one or more sex hormones after ACTH stimulation.

While some humans with pheochromocytoma have been found to have elevated 17-hydroxyprogesterone concentrations, other investigators have found false positive elevations of this hormone in dogs without hyperadrenocorticism. This indicates that cases tested for sex hormones during an ACTH response test should be carefully selected to include only those where hyperadrenocorticism is likely.

Dogs with adrenocortical adenocarcinomas have increased concentrations of sex steroids in response to ACTH



Primary Hyperaldosteronism in Cats

Javadi S, Djajadiningrat-Laanen SC, Kooistra HS, et al. Primary hyperaldosteronism, a mediator of progressive renal disease in cats. *Dom Anim Endocrinol* 2005;28:85-104.

► INTRODUCTION:

Background: Primary hyperaldosteronism caused by an aldosterone-secreting adrenal tumor has been described as an uncommon condition in cats resulting in hypertension, hypokalemia, and sometimes metabolic alkalosis. In humans, primary hyperaldosteronism occurs in other forms as well, including idiopathic hyperaldosteronism with associated adrenocortical hyperplasia. Elevated plasma aldosterone also occurs secondary to activation of the renin-angiotensin-aldosterone system due to decreased blood pressure in the renal afferent arteriole, decreased distal tubular sodium delivery, or beta-adrenergic stimulation of juxtaglomerular cells. Concurrent measurement of aldosterone and renin activity is necessary to distinguish primary and secondary forms of hyperaldosteronism. **Objectives:** The reason for this study was to describe hyporeninemic hyperaldosteronism in cats with hypertension and its effects on renal function.

✕ SUMMARY:

Methods: Of 11 cats found to have hyperaldosteronism, seven were presented for hypertensive retinopathy, three for hypokalemic paresis, and one with no clinical signs. Each had evaluation of the renin-angiotensin aldosterone system. Systolic blood pressure, and serum electrolytes, urea, and creatinine were measured in all cats. In addition, measurements of plasma renin, aldosterone, and the aldosterone: renin ratio were performed one or more times in all cats. Urine corticoid: creatinine ratio, low-dose dexamethasone suppression test, abdominal ultrasound examination, and abdominal computerized tomography (CT) were performed in some cats.

Results: Systolic blood pressure ranged from

185 to 270 mm Hg, and was above the reference limit of 195 mm Hg in seven cats. Serum creatinine was elevated in eight cats, and urea was elevated in five cases. Six cats were hypokalemic, three were hypercalcemic, and two of six were hypomagnesemic.

Adequate control of plasma potassium concentration and blood pressure are crucial in slowing progression of renal disease

Plasma aldosterone concentration was elevated in four of the 11 cats. Plasma renin activity was below normal in five cats and normal in the other six. Plasma aldosterone: renin ratio was elevated in all affected cats. Cortisol and ACTH secretion were considered normal on the basis of urine corticoid:creatinine ratio in three cats and low-dose dexamethasone suppression test in four cats. On abdominal ultrasound exam, adrenal glands were described as having a somewhat thickened cranial or caudal pole in one or both adrenal glands in three cats. Thickening of the caudal pole of one adrenal gland from one of these cats was also identified on CT. A unilateral adrenalectomy was performed on this cat, and the plasma aldosterone concentration decreased somewhat at five and 28 hours after surgery, but it was within the reference range prior to surgery. Plasma renin activity remained low after surgery. After two months of normokalemia, this cat developed hypokalemia again, although further renin and aldosterone measurements were not reported.

Treatments administered to the remaining cats included potassium supplementation, spironolactone, and beta-adrenergic blocker. Two of the cats were euthanized because of progressive renal failure while a progressive increase in serum urea and creatinine were noted in four others. Adrenal glands were examined by histopathology in three cats. Multiple small hyperplastic nodules comprised of large pale vacuolated cells that stained positive for neuron specific enolase were found.

Conclusions: The cats of this report had a syndrome similar to idiopathic hyperaldosteronism in humans, and it is frequently associated with progressive renal disease.

🌀 CLINICAL IMPACT:

It is unclear if the cats in this report truly had primary hyperaldosteronism or if the changes in plasma renin activity and aldosterone were the result of the renal failure that existed in most cats. Other studies in cats with chronic renal failure have documented normal or elevated aldosterone in the presence of normal or low plasma renin activity. It is not clear if the renal dysfunction resulted in hypokalemia, hypertension, and elevated aldosterone: renin ratio or if the hyperaldosteronism caused the hypertension, hypokalemia, and eventually renal damage. Regardless of the etiology, adequate control of plasma potassium concentration and blood pressure are crucial in slowing progression of renal disease.



Pressor Sensitivity to Norepinephrine in Dogs with Iatrogenic Hyperadrenocorticism

Martinez NI, Panciera DL, Abbott JA, et al. Evaluation of pressor sensitivity to norepinephrine infusion in dogs with iatrogenic hyperadrenocorticism. *Res Vet Sci* 2005;78:25-31.

► INTRODUCTION:

Background: One of the clinical signs of hyperadrenocorticism is hypertension. Although the pathogenesis is multifaceted, a major cause is believed to be glucocorticoid-induced hypersensitivity of catecholamine receptors. However, the degree of pressor sensitivity caused by iatrogenic hyperadrenocorticism in dogs is not known

Objectives: The purpose of this study was to evaluate pressor sensitivity to catecholamines in dogs with iatrogenic hyperadrenocorticism.

✕ SUMMARY:

Methods: Eight dogs with iatrogenic hyperadrenocorticism and eight healthy control dogs were given incremental doses of norepinephrine while serial measurements of arterial blood pressure were collected. Iatrogenic hyperadrenocorticism was produced by administering oral hydrocortisone at 3.3 mg/kg, every eight hours for 42–49 days. Control dogs were given a placebo. Norepinephrine intravenous infusions using a pump were 0.1, 0.15, 0.2, 0.3, 0.4, 0.6, and 0.8 µg/kg/min. Blood pressure measurement included systolic, diastolic, and mean pressures. Heart rate was also recorded.

Results: Dogs with iatrogenic hyperadrenocorticism had greater pressor responses than normal dogs to norepinephrine. Three of the control dogs developed severe hypertension (more than 240 mmHg) during the 0.8 µg/kg/min infusion, while seven of the eight dogs with iatrogenic hyperadrenocorticism developed severe hypertension during infusions from 0.15 to 0.8 µg/kg/min. The mean maximum tolerated dose in control dogs was 0.6 µg/kg/min; dogs with iatrogenic hyperadrenocorticism had a mean maximum tolerated dose of 0.34 µg/kg/min.

Conclusions: Dogs with iatrogenic hyperadrenocorticism have increased pressor sensitivity to norepinephrine.



CLINICAL IMPACT:

Approximately one-half of all cases of hyperadrenocorticism in dogs are iatrogenic in origin. Careful withdrawal from administered glucocorticoids can reverse the induced polyuria, polydipsia, enlarged abdomen, and hair loss. However, glucocorticoid-induced hypertension could cause irreparable damage, such as blindness from intraocular hemorrhage and retinal detachment, cerebrovascular accident, glomerulosclerosis, chronic renal failure, left ventricular hypertrophy, and congestive heart failure. Glucocorticoid therapy is a powerful therapeutic tool, but it should always be used at the lowest dose for the shortest period of time possible to attain the desired effects.

Glucocorticoid-induced hypertension could cause irreparable damage



Decreased Sodium:Potassium Ratios in Cats

Bell R, Mellor D, Ramsey I, et al. Decreased sodium:potassium ratios in cats: 49 cases. *Vet Clin Pathol* 2005;34:110-114.

► INTRODUCTION:

Background: Decreased sodium:potassium ratio is often used in dogs as an indication that hypoadrenocorticism may be present. While hypoadrenocorticism has been reported to be diagnosed in approximately 25% of dogs with a low sodium:potassium ratio, many other disorders, including urinary tract disease, gastrointestinal disorders, and effusions also cause this finding. Because hypoadrenocorticism is very rarely diagnosed in cats, it is not likely to account for most cases of low sodium:potassium ratio in this species.

Objectives: This retrospective study was carried out to determine the diseases associated with decreased sodium:potassium ratio in cats.

✕ SUMMARY:

Methods: Records of 49 cats with sodium:potassium ratios less than 27 and 50 cats with a normal sodium:potassium ratio evaluated over the same time period were reviewed.

Results: Hyperkalemia was present in all cats with a low sodium:potassium ratio. Gastrointestinal disease resulting in vomiting or diarrhea with inappetence was the most common finding in cats with a low sodium:potassium ratio, accounting for 12 cases. Two of these cats had ascites and hyponatremia. Urinary tract disease was found in 10 cats with a sodium:potassium ratio below 27. Eight had primary renal disease (4 with end-stage renal failure) and two had urinary outflow obstruction. Two cats with renal disease were receiving an angiotensin-converting enzyme inhibitor. One cat with urethral obstruction had effusion secondary to pulmonary trauma, and was the only cat in the group to have hyponatremia.

Endocrine disease was found in eight cats with a low sodium:potassium ratio, including five with diabetes mellitus and three with hyperthyroidism. Hyponatremia was present in two cats with diabetes mellitus. Elevated blood urea nitrogen and creatinine concentrations were noted in three diabetic cats and one cat with hyperthyroidism.

In addition, one hyperthyroid cat had a protein-losing nephropathy. One hyperthyroid cat was being treated with an angiotensin-converting enzyme inhibitor.

Eight cats were diagnosed with cardiorespiratory disease, including three with pleural effusion secondary to heart failure, two with aortic thromboembolism and primary heart disease, and one each with idiopathic chylothorax, bacterial pneumonia, and pulmonary contusion. Five other cats had other diseases including two with ocular, one with neurological, one with orthopedic, and one with allergic dermatitis. The decreased sodium:potassium ratio was due to artifact in six cats. Causes included contamination of the samples with potassium EDTA and lipemia. Overall, five cats had pleural effusion and three had abdominal effusions, including one cat with uroabdomen. The effusion had not been removed in any cat prior to blood sampling.

Hyperkalemia was present in only one cat in the control group while it was found in all cats with a low sodium:potassium ratio. Hyponatremia was present in nine cats with a low sodium:potassium ratio and four control cats. There was no significant difference in the mean sodium concentration between the two groups. Of the nine cats with a low sodium:potassium ratio and hyponatremia, four had an effusion. Hypoadrenocorticism was not diagnosed in any cat of this study.

Conclusions: Low sodium:potassium ratio is found in many diseases in the cat, particularly effusions.

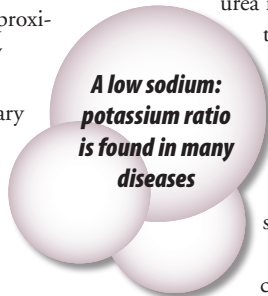


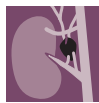CLINICAL IMPACT:

The most common cause for a depressed sodium:potassium ratio in cats of this study was gastrointestinal disease. A close second cause was urinary disease.

It is important to note that significant electrolyte abnormalities were found in cats with effusions prior to withdrawal of fluid from the body cavities, unlike most previous reports that suggested loss of fluid and electrolytes through repeated centesis was important in causing the hyperkalemia and hyponatremia. Hypovolemia and decreased renal perfusion likely played a role in development of hyperkalemia in many cases in this study, including cats with dehydration due to gastrointestinal or endocrine disease, congestive heart failure, and effusions.

Just nine of the 49 cases of this report with a reduced sodium:potassium ratio had concurrent hyponatremia and hyperkalemia. Deficiency of aldosterone from primary hypoadrenocorticism does not selectively alter sodium or potassium. Patients with hyponatremia and normal potassium concentration or hyperkalemia and normal sodium concentration are not strong candidates for primary hypoadrenocorticism. However, any patient—dog or cat—should be evaluated specifically for primary hypoadrenocorticism if they have concurrent hyponatremia and hyperkalemia.





Metastatic Tumors to the Adrenal Glands

Labelle P, De Cock HEV. Metastatic tumors to the adrenal glands in domestic animals. *Vet Pathol* 2005;42:52-58.

► INTRODUCTION:

Background: The adrenal glands are highly vascular. In humans, the adrenals are the fourth most common site for metastases after the lung, liver, and bone. Hypoadrenocorticism can result but more than 90% of both glands' cortices must be compromised. At that point, problems from other metastases or the primary tumor have usually endangered life. The incidence of metastatic tumors to the adrenal glands and metastasis-caused hypoadrenocorticism in domestic animals has not been well investigated.

Objectives: The purpose of this retrospective study was to investigate the incidence of metastasis to the adrenal glands, the types of malignant tumors that metastasize to the adrenal glands, and the rate at which metastatic tumors are the cause of adrenal gland tumors in the dog, cat, horse, and cow.

✕ SUMMARY:

Methods: A retrospective investigation of the medical records of dogs, cats, horses, and cattle that had metastatic disease was conducted.

Results: The rate of adrenal involvement in dogs was 21% (112 of 534 dogs) and in cats was 15% (12 of 81 cats). Dogs had 26 types of tumors metastasize to the adrenals. Most common metastases were carcinomas from the lungs, mammary glands, prostate, stomach, or pancreas. Either the adrenal cortex or the medulla, or both, were sites of metastasis. Melanoma was the only nonepithelial tumor with metastasis rate above the canine average of 21%. All melanoma metastases to the adrenals were confined to the medulla. Lymphoma was the most common source of adrenal metastases in cats. Although metastasis was present bilaterally in 55% of dogs with adrenal metastasis, only one dog and no cats

developed hypoadrenocorticism from tumor (lymphoma) metastasis. Based on the number of metastatic lesions in other tissues in animals with adrenal metastasis, metastasis to adrenals occurs late in the spread of malignancies.

Among all adrenal tumors, 27% were metastatic in dogs and 60% were metastatic in cats.

Conclusions: The incidence of malignant tumor metastasis to the adrenal gland is high. The adrenal glands should be thoroughly examined during clinical evaluations or necropsies when disseminated neoplasia is suspected.

The assumption of a primary adrenal tumor would be incorrect in about one-fourth of the cases in dogs and in more than half of cats with adrenal masses detected by ultrasonography



CLINICAL IMPACT:

Ultrasonographic assessment of the size of the adrenals has become a common diagnostic examination in dogs and cats. The first assumption if an adrenal mass is observed is usually that the cause is either an primary adrenocortical tumor or a pheochromocytoma. Based on the results of this study, the assumption of a primary adrenal tumor would be incorrect in about one-fourth of the cases in dogs and in more than half of cats with adrenal masses detected by ultrasonography. The risk of hypoadrenocorticism caused by metastatic infiltration to the adrenal gland is low, late in the progression of metastasis, and likely to be overshadowed by other problems related to the primary tumor or other metastases.



Spontaneous Hypoadrenocorticism After a Diagnosis of Hyperadrenocorticism

Rockwell JL, Monroe WE, Tromble TC. Spontaneous hypoadrenocorticism in a dog after a diagnosis of hyperadrenocorticism. *J Vet Intern Med* 2005;19:255-258.

► INTRODUCTION:

Background: Hypoadrenocorticism following diagnosis of hyperadrenocorticism is common in dogs treated with mitotane and also occurs occasionally in dogs administered trilostane. This phenomenon occurs in some cases independent of the dose of mitotane, and the mechanism of adrenal failure is poorly understood. Spontaneous primary adrenocortical failure in a dog previously with hyperadrenocorticism and not receiving treatment has not been previously reported.

Objectives: The purpose of this report was to describe an unusual case of a dog with hypoadrenocorticism that developed soon after the diagnosis of hyperadrenocorticism.

✕ SUMMARY:

Case Report: A 7-year-old, mixed breed, spayed female dog was evaluated for lethargy, anorexia, and vomiting of seven days duration. One month prior to this, the dog was diagnosed with hyperadrenocorticism based on a history of polyuria, polydipsia, polyphagia, elevated alkaline phosphatase activity, and marked elevation of plasma cortisol concentration on an adrenocorticotrophic hormone (ACTH) stimulation test. After this report was published, the dog developed neurologic signs consistent with a pituitary macroadenoma 10 months after initial presentation and was euthanized.

At the time of presentation for the more recent illness, the dog was weak, lethargic, and had weak femoral pulses. Abnormalities on routine laboratory tests included mild eosinophilia, mild azotemia with hyperphosphatemia, hyponatremia, hyperkalemia, hypochloremia, and metabolic acidosis. Urine specific gravity was 1.016. Results of an ACTH response test revealed very low plasma cortisol and aldosterone concentra-

tions, consistent with a diagnosis of primary hypoadrenocorticism. The endogenous plasma ACTH concentration was markedly elevated.

Hypoadrenocorticism was caused by hyperadrenocorticism-associated bilateral infarction of the adrenal glands

Abdominal ultrasound revealed symmetrical enlargement of the adrenal glands and no evidence of adrenal gland perfusion based on Doppler imaging. Following treatment with intravenous fluid therapy and hydrocortisone, a computerized tomograph of the abdomen showed bilateral adrenal enlargement with moderate peripheral contrast enhancement of the outer rim of the adrenal cortex, and contrast uptake in the area of the adrenal medulla. Fine needle aspirate cytology of the adrenal glands was consistent with severe necrosis and purulent inflammation. These findings were considered to be consistent with decreased vascular perfusion of the adrenal cortex.

Treatment with prednisone and fludrocortisone, followed by prednisone and desoxycorticosterone pivalate was effective in managing the disease for 10 months, at which time the dog developed neurologic signs and was euthanized. The authors confirmed at necropsy that the dog had a chromophobe macroadenoma of the pituitary gland and bilateral necrosis of the adrenal cortex.

Conclusions: Hypoadrenocorticism was caused in the dog of this report by hyperadrenocorticism-associated bilateral infarction of the adrenal glands.

🌀 CLINICAL IMPACT:

This case report provides a convincing description of acute adrenocortical necrosis in a dog with pituitary-dependent hyperadrenocorticism. Because adrenocortical failure occurred very soon after an ACTH response test, it is possible that the acute increase in ACTH caused adrenal gland hemorrhage or necrosis as

has been reported to occur rarely in humans. It is possible that the acute adrenocortical insufficiency that occurs in occasionally in dogs treated with trilostane or relatively low doses of mitotane could occur through a similar mechanism of increased ACTH. On the other hand, the hypercoagulable state found in hyperadrenocorticism or other changes in the hyperplastic tissue could have resulted in adrenal cortical necrosis. Regardless of the pathogenesis, acute adrenocortical necrosis is a rare finding in dogs with hyperadrenocorticism.



Seminoma with Hyperestrogenemia

Kim O, Kim KS. Seminoma with hyperestrogenemia in a Yorkshire terrier. *J Vet Med Sci* 2005;67:121-123.

► INTRODUCTION:

Background: Testicular tumors are diagnosed more often in older dogs than in any other domestic species. The three most common testicular neoplasms (Sertoli cell tumor, interstitial cell tumor, and seminoma) occur with nearly equal frequency. Sertoli cell tumors are often associated with feminization, and interstitial cell tumors may be associated with increased virilization or with feminization. Seminomas are rarely associated with gonadal endocrinopathy.

Objectives: The objective of this report was to describe a dog with a seminoma, hyperestrogenism, and alopecia.

✕ SUMMARY:

Case Report: An 8-year-old, male, Yorkshire terrier was presented with unilateral cryptorchidism for anorexia and bilateral alopecia. Abdominal radiographs and ultrasonograms revealed a mass in the abdomen suspected to be an enlarged cryptorchid left testicle. Both testes were surgically removed. Serum testosterone and estradiol were collected from the jugular vein and from the spermatic vein of each testicle. Serum estradiol concentrations were higher than the control, especially in the venous blood from the left testicle. The left testicle was enlarged, and the cut surface was a homogeneous white color. The histologic diagnosis was a seminoma. The right testicle was atrophied with an enlarged epididymis. No other testicular tumors were found. Three months after the castration, the dog had regrown hair in the formerly alopecic areas.

Conclusions: This Yorkshire terrier had a rare case of a seminoma in a cryptorchid testicle on the left side with hyperestrogenism.



CLINICAL IMPACT:

Although they are few, other cases of feminization associated with a seminoma have been reported in dogs. Finding of elevated estradiol concentration in the venous blood from the tumor is incriminating that the seminoma had developed a complex steroidogenesis pathway to the production of estradiol. If this was the case and other, undiscovered, tumors within the testicle with a seminoma were not actually the source of estradiol, the course of events leading to developing a steroidogenesis pathway to estradiol by spermatogenic cells is probably very rare. Feminization caused by testicular tumors is usually caused by Sertoli cell tumors or, less commonly, by interstitial cell tumors.

Feminization caused by testicular tumors are usually caused by Sertoli cell tumors or, less commonly, by interstitial cell tumors

Thyro-Tabs[®]

(levothyroxine sodium tablets, USP)

Caution: Federal law restricts this drug to use by or on the order of a licensed veterinarian.

Description:

Each Thyro-Tabs[®] tablet provides synthetic crystalline levothyroxine sodium (L-thyroxine).

Indications:

For use in dogs for correction of conditions associated with low circulating thyroid hormone (hypothyroidism). Low serum circulating T-4 concentrations, coupled with clinical signs, are suggestive of hypothyroidism. The following T-4 concentrations in canine serum have been established:

Normal (euthyroid) – 18 to 32 ng/mL (18 to 32 µg/dL)

Possible hypothyroid - 10 to 18 ng/mL (10 to 18 µg/dL)

Hypothyroid – less than 10 ng/mL (10 µg/dL)

Hypothyroidism is unlikely with a resting serum T-4 concentration of 18 ng/mL or above. A dog exhibiting signs of hypothyroidism with a T-4 below 18 ng/mL should be considered for levothyroxine replacement therapy. Confirmation of the diagnosis could include withdrawal of therapy after which a recurrence of clinical signs further supports the diagnosis. Correct diagnosis of hypothyroidism is important, since such a diagnosis normally commits an animal to life-long replacement therapy. The principle objective of levothyroxine sodium administration is to achieve and maintain normal metabolism in the animal's normal physiologic range. Animal adaptation may necessitate regular monitoring of serum T-4 concentrations during the first several months of treatment to establish maintenance doses. TSH testing may be used to provide a definitive diagnosis in dogs with borderline resting T-4 values.

Mode of actions:

Levothyroxine sodium provided by Thyro-Tabs cannot be distinguished from that endogenously secreted by the thyroid gland. The primary regulator of thyroid function is thyroid stimulating hormone (TSH) which is synthesized and secreted by the pars distalis of the adenohypophysis (anterior pituitary). The mediator from the hypothalamus which exerts a continuous influence over the release of TSH is

thyrotropin-releasing hormone (TRH).

Hypothyroidism in the dog:

Hypothyroidism usually occurs in older and middle-aged dogs although the condition will sometimes be seen in younger dogs of the larger breeds. Neutered animals of either sex are also frequently affected, regardless of age. The condition is primary failure of the thyroid gland because of lymphocytic thyroiditis or other loss of follicular epithelium and resulting atrophy of the gland. Secondary hypothyroidism is rare and usually due to a destructive pituitary tumor.

Clinical signs:

The following list of clinical signs and laboratory findings may vary depending upon the degree of thyroid dysfunction:

Nerve and muscle function: lethargy, lack of endurance, increased sleeping, reduced alertness and interest with dulled mental attitude, hypotonus, stiff, slow movements, dragging of forelimbs, head tilt, disturbed balance, unilateral facial paralysis.

Metabolism: decreased oxygen consumption and lower metabolic rate, sensitivity and intolerance to cold, low body temperature, cool skin, heat seeking, increased body weight, constipation, poor exercise tolerance, slow heart rate, weak pulse, weak apex heart beat and low voltage on ECG.

Reproduction: reproductive failure, abortion, stillbirth, live birth of weak young, delayed puberty, reduced libido, impaired spermatogenesis, irregular estrus and anestrus, galactorrhea.

Skin and hair: myxedema of the face, blepharoptosis, atrophy of epidermis, thickening of the dermis, surface and follicular hyperkeratosis, hyperpigmentation, coarse and sparse coat, dry, dull and brittle hair, slow regrowth and retarded turnover of hair and bilateral alopecia.

Laboratory findings: low serum T-4 concentrations, hypercholesterolemia, hypertriglyceridemia, elevated serum creatine kinase, normochromic, normocytic anemia.

Contraindications:

Therapy is contraindicated in thyrotoxicosis, acute myocardial infarction, and uncorrected adrenal insufficiency. Other conditions in which the use of therapy should be used with caution include primary hypertension, euthyroidism, and pregnancy.

Precautions:

The administration of levothyroxine sodium to dogs to be used for breeding purposes or in pregnant bitches has not been evaluated. There is evidence that administration to pregnant bitches may affect the normal development of the thyroid gland in the unborn pups. The clinical effects of therapy are slow in being manifested. Overdosage may produce the signs of thyrotoxicosis including but not limited to: polydipsia, polyuria, polyphagia, reduced heat tolerance and hyperactivity or personality change. Thyro-Tabs 0.1 mg and 0.7 mg tablets contain FD&C yellow #5 (tartrazine) which has been associated with allergic-type reactions (including bronchial asthma) in susceptible humans. It is unknown if such a reaction could also occur in dogs.

Adverse reactions:

There are no specific adverse reactions associated with therapy at the recommended dosages. Overdosage will result in thyrotoxicosis.

Dosages:

The initial recommended daily dose is 0.1 to 0.2 mg/10 pounds (4.5 kg) body weight in single or divided doses. Dosage is adjusted by monitoring T-4 blood levels of the dog every four weeks until an adequate maintenance dose is established. The usual daily maintenance dose is 0.1 mg/10 pounds (4.5kg). A maximum of 0.8 to 1.0 mg total daily dose will be sufficient in many dogs over 80 pounds in body weight.

Administration:

Thyro-Tabs may be administered orally or placed in the food.

How supplied:

Available as scored, color-coded caplets in 9 concentrations: 0.1 mg, 0.2 mg, 0.3 mg, 0.4 mg, 0.5 mg, 0.6 mg, 0.7 mg, 0.8 mg and 1.0 mg in 28 tablet strip packs, bottles of 120 and 1,000.

Storage:

Store at controlled room temperature; 15°-30°C (59°-86°F) and protect from light.

References: See package insert.



A Division of LLOYD, Inc.

For more information call
1-800-831-0004

Revised July 2006

Journals examined by the editors for article inclusion:

American Journal of Veterinary Research
Australian Veterinary Journal
Canadian Journal of Veterinary Research
Canadian Veterinary Journal
Domestic Animal Endocrinology
Endocrinology
European Journal of Endocrinology
Journal of Veterinary Internal Medicine
Journal of the American Animal
Hospital Association
Journal of Small Animal Practice
Journal of the American Veterinary
Medical Association

Journal of Veterinary Diagnostic Investigation
Journal of Veterinary Medical Science
Journal of Veterinary Medicine, Series A
Journal of Comparative Pathology
Journal of Veterinary Pharmacology
and Therapeutics
New Zealand Veterinary Journal
Research in Veterinary Science
Veterinary Journal
Veterinary Pathology
Veterinary Record
Veterinary Radiology & Ultrasound
... and more than 20 others

Editors

C. B. Chastain, DVM, MS
Dip ACVIM (Internal Medicine)
Professor, Companion Animal Medicine
Department of Veterinary
Medicine and Surgery
College of Veterinary Medicine
University of Missouri
Columbia, MO 65211

Dave Panciera, DVM, MS
Dip ACVIM (Internal Medicine)
Professor, Small Animal Medicine
Department of Small Animal
Clinical Sciences
Virginia-Maryland Regional College
of Veterinary Medicine
Blacksburg, VA 24061

LLOYD
INCORPORATED

Copyright © 2006 Lloyd Incorporated,
All rights reserved.

No part of this publication may be reproduced by any means whatsoever without the express written permission of the authors.

DISCLAIMER

Lloyd Incorporated presents the article summaries contained in this publication as a courtesy to medical professionals. Lloyd Incorporated has no knowledge as to the efficacy, safety, or appropriateness of any of the treatments or information set forth in the summaries and makes no representation as such. If you have any questions or desire additional information with regard to any of the material in this publication, you must contact the author of the original articles.